

PATIENT

Jordy Seim

SPECIES

Canine

BREED

Cavalier

SEX

Male Neutered

AGE

11 years

WEIGHT

20lbs; 9.1kgs

INTERPRETED BY

Maggie Machen Lamy,
DVM, DACVIM
(Cardiology)

IMAGING PERFORMED BY

Kara Wallisch, DVM

HOSPITAL NAME

Sondel Family
Veterinary Clinic

REFERRING VET

Dr. Wallisch

INVOICE

29110

DATE

2/10/23

PRESENTING CLINICAL SIGNS

History: Recheck echo; previous report not available for comparison. No current symptoms, doing well.

-Current medications: Pimobendan 3.75mg BID; Amlodipine 5mg: 1/2 tab in AM and 1 tab in PM; Enalapril 5mg BID.

ECHOCARDIOGRAM FINDINGS

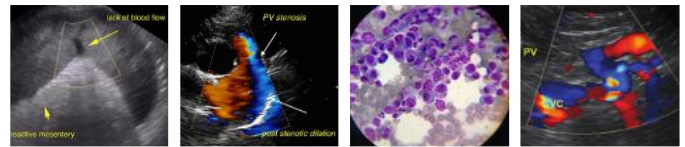
2D, m-mode, color flow and doppler imaging is available. Diffuse thickening of mitral valve leaflets (anterior>posterior) with mild prolapse into the left atrial lumen. Moderate eccentric mitral regurgitation with moderate left atrial dilation. Normal MR velocity. Mildly increased LV diameter with hyperdynamic myocardial function. The tricuspid valve appears subjectively normal, with mild tricuspid regurgitation. Normal velocity. Normal right atrial and ventricular diameter. The pulmonic and aortic valves are normal in morphology and mobility. Normal pulmonic and aortic outflow velocities. No aortic and trace pulmonic insufficiency. No pericardial or pleural effusion noted. No cardiac tumors observed.

CARDIAC CHART

CANINE CARDIAC PARAMETERS	MR VMAX (m/s)	TR VMAX (m/s)	LA/AO (Boon method)	LA/AO (Heart Base; Swe)	FS (%)	EF (%)	EPSS (cm)
NORMAL PARAMETER	4.5-5.5	<2.7	1.3	<1.6	28-40	40-100	<0.6
PATIENT	5.5	2.5	NM	1.8	43	80	NM
CANINE CARDIAC PARAMETERS	HR (BPM)	AV VMAX (m/s)	PV MAX (m/s)	BODY WEIGHT (kg)	LA 2D short axis Base view (cm)	LVIDd Avg; 2D and m-mode short axis (cm)	LVIDs Avg; 2D and m-mode short axis (cm)
NORMAL PARAMETER	50-100	0.7-1.7	0.7-1.6	BELOW	BELOW	BELOW	BELOW
PATIENT	NM	0.8	0.8	9.1	2.9	3.5	2.0
*Normal chamber parameters expressed as a mean value (SD)				3	1.27 (5.3)	2.46 (2.46)	1.36 (5.5)
BODY WEIGHT DEPENDENT PARAMETERS				5	1.40 (4.5)	2.74 (5.2)	1.60 (4.7)
<i>*Note: All measurements based upon multi-modal images and methods. An average value is reported.</i>				10	1.50 (3.8)	3.27 (3.5)	2.06 (3.1)
				15	1.83 (2.0)	3.71 (2.4)	2.43 (2.1)
				20	2.02 (1.9)	4.14 (2.2)	2.80 (2.0)
				25	2.18 (2.4)	4.48 (2.9)	3.10 (2.5)
				30	2.33 (3.3)	4.83 (3.9)	3.39 (3.4)
				35	2.48 (4.3)	5.17 (5.0)	3.69 (4.5)
				40	2.62 (5.2)	5.48 (6.1)	3.96 (5.4)
				50	2.88 (7.1)	6.07 (8.3)	4.46 (7.4)

INTERPRETATION OF THE FINDINGS & FURTHER RECOMMENDATIONS

Chronic degenerative valve disease causing moderate mitral and mild tricuspid regurgitation. Moderate left atrial enlargement indicates there is relatively low risk for imminent complication, however risk for progression to spontaneous congestive heart failure in the future is elevated. No additional issues are identified. Based upon the medications, this presumably reflects persistent stage B2 disease.



PATIENT

Jordy Seim

Given these findings, reasonable to continue Pimobendan and Enalapril as prescribed. Amlodipine is of unknown benefit at this stage; however, routine blood pressure monitoring is recommended. Assessment of progression in the future will help predict long term outcome, however prognosis is guarded at this stage (B2).

SPECIES

Canine

Omega fatty acid supplementation and mild salt restriction may also be of some long term benefit. Monitor for development of a progressive cough, labored breathing, exercise intolerance or collapse episodes.

BREED

Cavalier

Anesthetic risk is considered mildly elevated. Cardiac protective drug choices (opioid/benzodiazepine premedication, Propofol or alfaxalone induction, iso or sevo gas) are recommended. Monitor for arrhythmias, hypotension, and hypoxia both intra and post-operatively and intervene as necessary. Judicious IV fluid rates are recommended to avoid fluid overload. Avoid heart rate stimulating drugs such as atropine unless clinically indicated.

SEX

Male Neutered

AGE

11 years

PLAN

Continue Pimobendan and Enalapril as prescribed. Pending BP >130mmHg, reasonable to continue Amlodipine.

WEIGHT

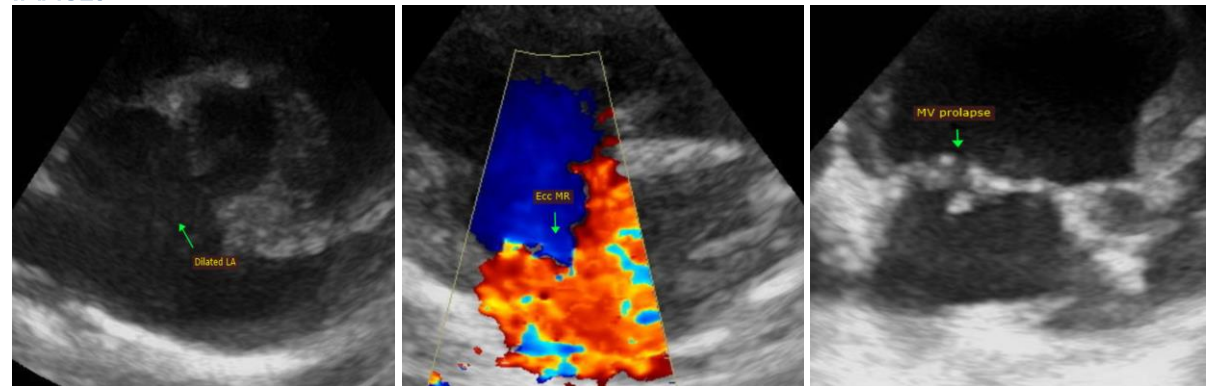
20lbs; 9.1kgs

Recommend monitor for progression with a recheck echocardiogram in 6 months, sooner if any development of clinical signs.

IMAGES

INTERPRETED BY

Maggie Machen Lamy,
DVM, DACVIM
(Cardiology)



IMAGING PERFORMED BY

Kara Wallisch, DVM

HOSPITAL NAME

Sondel Family
Veterinary Clinic

REFERRING VET

Dr. Wallisch

The information and recommendations provided are based on the images presented by the referring veterinarian. No evaluation can be communicated regarding pathology that was not visible in the image/video clips provided.

Thank you for this referral. This report was generated using transcription software, and minor dictation errors may be present. If the clinical or image interpretation does not parallel your findings or if I can be of any further assistance, please contact me.

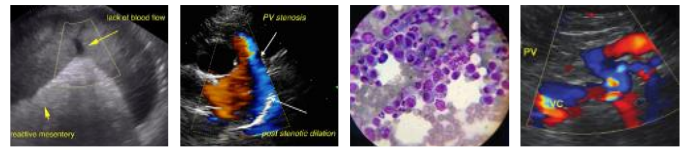
INVOICE

29110

Maggie Machen Lamy, DVM
Diplomate of the American College of Veterinary Internal Medicine (Cardiology)
info@sonopath.com

DATE

2/10/23



PATIENT

Jordy Seim

SPECIES

Canine

BREED

Cavalier

SEX

Male Neutered

AGE

11 years

WEIGHT

20lbs; 9.1kgs

INTERPRETED BY

Maggie Machen Lamy,
DVM, DACVIM
(Cardiology)

**IMAGING
PERFORMED BY**

Kara Wallisch, DVM

HOSPITAL NAME

Sondel Family
Veterinary Clinic

REFERRING VET

Dr. Wallisch

INVOICE

29110

DATE

2/10/23